

M. ZAVIACIC ; T. ZAVIACIC ;
R.J. ABLIN ; J.BREZA ;
K. HOLOMAN

Résumé : Reinier de Graaf, physiologiste et histologiste allemand, fut le premier à décire la prostate féminine, à lui attribuer ce terme et à essayer de déterminer la fonction de cet organe. La description qu'en fit le gynécologue Américain Alexander J.C. Skene fut l'objet d'un grand débat qui fit passer au second plan les élégantes études d'Huffman. Au début du xx^e siècle, la prostate féminine, référencée sous le nom de "glandes et canaux de Skène", passe pour un vestige sans importance pour la vie de la femme. La présence de PSA et de paramètres structuraux fonctionnels, ainsi qu'une pathologie, identique à celle de l'homme, mettent en évidence qu'il s'agit bien d'un équivalent prostatique chez la femme. En 2001 le FICAT* a accepté le terme de prostate et la 4^e édition de la terminologie histologique la cite comme telle. Les recherches contemporaines montrent que la prostate de la femme a un poids du 1/5 au 1/4 de celle de l'homme adulte, elle est située dans la paroi de l'urètre et, malgré un espace limité, elle possède un équipement cellulaire muni d'un fonctionnement exocrine (fluide prostatique féminin), et neuro-endocrine. Par ailleurs, on retrouve les mêmes types et structures cellulaires que dans la prostate de l'homme, avec les mêmes fonctions. L'auteur conclut que cela implique d'abandonner le terme de glandes de Skène, car le terme de prostate féminine est pleinement justifié. La décision du FICAT qui introduit le terme de *prostata feminina* respecte les nouvelles données de la recherche.

MOTS-CLEFS :

- Prostate féminine (glandes et canaux de Skene para-urétraux)
- Historique
- Anatomie
- Histologie
- Ultrastructure
- Enzymes, PSA

KEY WORDS :

- Female prostate (Skene's para-urethral ducts and glands)
- History
- Anatomy
- Histology
- Ultrastructure
- Prostate-specific antigen (PSA)
- Enzymes

La prostate féminine* : historique, morphologie fonctionnelle et implications en sexologie**

* Le *Federative International Committee on Anatomical Terminology (FICAT)* à la conférence d'Orlando (2001) a accepté de mentionner le terme de "prostate féminine" (*prostata feminina*) dans la nouvelle édition de la terminologie histologique. Cette décision remplace la terminologie "glandes et canaux para-urétraux de Skene".
** Des extraits de cette publication ont été présentés au 15^e *World Congress of Sexology*, Paris, 24-28 juin, 2001.

Histoire

Reinier De Graaf, physiologiste et histologiste des Pays-Bas (1641-1673), un an avant sa mort, dans le traité *De mulierum organis generationi inservientibus...* avait pour la première fois avec une précision exemplaire pour son époque, décrit la structure essentielle de la prostate féminine, formée par des glandes et canaux présents autour de l'urètre féminin. De Graaf avait été le premier à essayer de formuler la fonction de cette prostate féminine en écrivant : "La fonction de la prostate (*corpus glandulosum*) consiste à libérer un liquide glairo-séreux qui augmente la libido de la femme, la rend plus désirable par son odeur acre et salée, et lubrifie ses parties génitales pendant le coït" (Jocelyn et al. 1972). Même si sa conception de la prostate féminine était plus basée sur l'intuition que sur une recherche effective, De Graaf en est sans doute le découvreur. Par la suite, ce sont des personnages comme lui travaillant dans le domaine de la médecine et de la biologie, Astruc, Virchow et d'autres, cités par Huffman (1948) et plus tard Stifter (1988) qui se sont intéressés à ce problème (Zaviacic, 1999).

Le rôle du gynécologue américain Alexandre J.C. Skene (1838-1900) dans ce domaine reste controversé. Bien que A.J.C. Skene (1880) ait décrit ces structures 200 ans plus tard que De Graaf et que ses conclusions aient été déjà controversées il y a 50 ans (Huffman 1948, 1951), jusqu'ici la prostate féminine est encore connue sous le nom de Skene dans les milieux urologiques et gynécologiques; et ce terme – glandes

et canaux para-urétraux de Skene – est toujours utilisé en médecine clinique; dans la terminologie anatomique parisienne (*Pariensia Nomina Anatomica*, 1955) on ne mentionnait plus les éponymes (Zaviacic, 1999; Zaviacic et Ablin, 2000). Ce n'est qu'en 2001 que le FICAT a proposé d'introduire le terme de prostate féminine dans la nouvelle édition de la *Terminologie Histologique*. Les travaux de la première moitié du xx^e siècle sur la physiologie et la pathologie de la prostate féminine (Evatt, 1911; Johnson, 1922; Korenchevsky, 1937; Petrova et al. 1939; Caldwell, 1941; Folsom et O'Brien 1943, 1945; Deter et al. 1946) ont fait progressivement évoluer l'opinion sur ce petit organe féminin. Mais cela n'avait pas influencé la tendance dominante selon laquelle la prostate féminine (appelée glandes et canaux para-urétraux de Skene) était considérée comme un organe féminin sans importance, rudimentaire, "vestigial" ne jouant aucun rôle dans la vie de la femme. Sa conception vestigiale était basée sur la différence de volume qu'elle présentait dans les deux sexes.

Pour la majorité des médecins, l'origine embryologique commune des deux glandes (chez la femme et l'homme) n'était pas un argument suffisant pour conclure à une homologie des deux structures. (Campbell, 1954; Egloff, 1972; Kurman, 1994).

Ce qui a permis progressivement d'imposer une conception non-vestigiale de la prostate féminine, ce sont les travaux d'Huffman (1948, 1951), dont peut considérer qu'ils marquent le début de l'histoire moderne de cette approche. Huffman (1948) avait étudié cet organe sur des

maquettes en cire sur la base desquelles nous avons fait une analyse histologique de 150 tubes urétraux de tissus de prostate féminine prélevés lors d'autopsies (Zaviacic, 1999; Zaviacic et al. 2000).

La recherche intensive actuelle dans ce domaine, dont le début se situe dans la première moitié des années 1980, permet de démontrer que ce petit organe de l'appareil génito-urinaire de la femme a une structure, une fonction, et une pathologie définies. D'autres paramètres comparables à ceux de la prostate masculine (Zaviacic, 1999) ont été trouvés progressivement dans la prostate féminine.

À présent, les urologues et les gynécologues ont un intérêt grandissant pour cet organe surtout depuis les nouvelles connaissances sur l'antigène spécifique prostatique (PSA) et ses implications chez la femme. Comme la prostate masculine, la prostate féminine est la source essentielle de ce marqueur chez la femme (Zaviacic, Ablin, 1998, 2000). De même, la pathologie de la prostate féminine (carcinome, hyperplasie bénigne prostatique, prostatite, prostatisme) (Zaviacic, 1999), ainsi que d'autres données cliniques en rapport avec sa fonction (aspects sexologiques, médico-légaux, gynéco-urologiques, chronobiologiques) intéressent les cliniciens (Zaviacic, 1999).

Pendant ces 20 dernières années, une grande activité de publication a changé notre opinion sur ce petit organe féminin, et on en a gagné progressivement du terrain en matière de comparaison avec la prostate masculine (Zaviacic, 1999). Nous espérons par nos travaux de ces 17 années passées avoir contribué à l'acquisition des connaissances dans ce domaine (Zaviacic, 1999).

Anatomie, morphologie fonctionnelle et implications en sexologie

Le poids moyen de la prostate d'une femme adulte est 5,2 g (Zaviacic et al. 2000) et elle représente ainsi à peu près 1/5 à 1/4 du poids moyen de la prostate normale (23,7 g) d'un homme adulte (Thackray, 1978; Williams et Warwick, 1980; Petersen, 1994).

Sur le plan histologique, elle est composée des mêmes éléments que ceux de la pros-

tate de l'homme; c'est-à-dire des glandes, canaux et muscles lisses (Huffman, 1948; Mallon, 1983; Zaviacic et al. 1983; Tepper et al. 1984). Il y a plus de fibres musculaires lisses dans la prostate féminine que dans celle de l'homme. Les canaux prostatiques (para-urétraux) n'aboutissent pas dans la vulve aux côtés du méat urinaire mais s'ouvrent tout le long de la lumière urétrale (Zaviacic, 1999).

La différence de base entre les prostates masculine et féminine réside dans la localisation du tissu prostatique. Alors que la prostate de l'homme entoure la partie prostatique de l'urètre, chez la femme c'est tout l'urètre qui lui correspond (Egloff, 1972) (Figure 1). C'est la raison essentielle du volume moins important de la prostate féminine. Malgré cela, elle est constituée de tous les éléments (glandes, canaux, musculature lisse) caractérisant la prostate masculine, y compris le "matériel" cellulaire, enzymatique etc. permettant ses fonctions exocrine et neuro-endocrine (Zaviacic, 1987, 1999; Zaviacic et Whipple, 1993; Zaviacic et al. 1997). Ces fonctions, surtout l'exocrine, ont des implications importantes dans divers champs médicaux (Zaviacic et al. 1985; Zaviacic, 1987; Zaviacic et Whipple,

1993; Zaviacic et Ablin, 1998, 2000).

Les maquettes en cire de la prostate féminine d'Huffman (1948) restent d'actualité même après 50 ans. Nous avons confirmé qu'il existait plusieurs types de prostates féminines, ce qui n'existe pas chez l'homme; ce travail a été basé sur l'étude d'un matériel d'autopsie beaucoup plus important (150 tubes urétraux-prostates féminins) que celui dont avait disposé Huffman (Huffman, 1948). Ce dernier avait déjà signalé que le tissu prostatique féminin était plus riche dans la partie distale de l'urètre, et, plus tard, d'autres auteurs (Zaviacic, 1987, 1999; Wernert et al. 1992) l'ont également confirmé. Nous avons appelé ce type de prostate "type antérieur" (méatal) (Figure 2). Il est présent chez 66 pour cent (58-74 %) des femmes; c'est le type le plus fréquent (Zaviacic, 1987, 1999; Zaviacic et al. 2000). Eichel et al. (1988) et Eichel (1997) soulignent l'importance du type méatal de la prostate féminine pour l'obtention de l'orgasme coïtal car, pendant les mouvements coïtaux la partie antérieure de l'urètre féminin est stimulée par la pression et les mouvements des organes génitaux.

Plus tard, Eichel (1997) a attiré notre attention sur le point de Gräfenberg (point G),

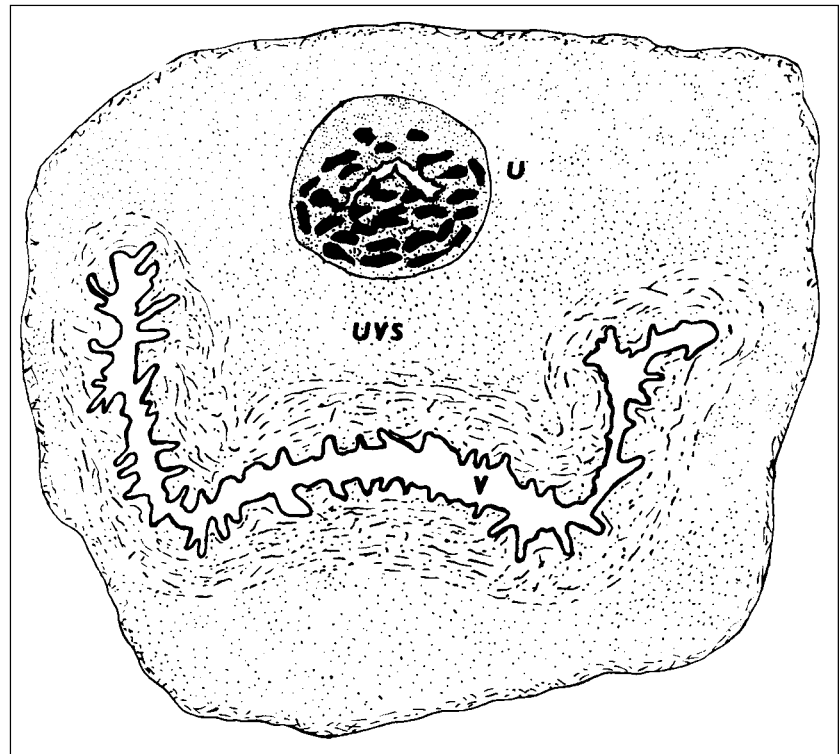


Figure 1 : Le tissu de la prostate féminine dans la paroi de l'urètre féminin (U). Une relation entre l'urètre féminin (U), le tissu prostatique, le septum uréthro-vaginal (UVS) et le vagin (V) est démontrée.




Figure 2 : Le type "antérieur (méatal)" de la prostate féminin selon la maquette en cire de Huffman (26).

zone érogène de la paroi antérieure du vagin (Gräfenberg, 1950; Perry and Whipple, 1981; Ladas et al. 1982).

"Le type postérieur" de prostate féminine, caractérisé par la présence de tissu prostatique plus riche dans l'urètre postérieur vers le col vésical, n'a été retrouvé que dans 10 % de nos études sur pièces d'autopsie. C'est seulement dans ce nombre de cas relativement faible qu'il pourrait y avoir une correspondance entre point G et localisation de tissu prostatique féminin. Le type de prostate "urètre total" n'a été trouvé que dans 6 % de nos cas d'autopsie (Zaviacic, 1999; Zaviacic et al. 2000). Bien que ce type soit relativement rare, on le présente souvent à tort comme un modèle classique de prostate féminine.

La forme "rudimentaire" de la prostate était dans notre matériel caractérisée par l'absence de glandes et de canaux sur la plupart des coupes de l'urètre examinées et elle représente 8 % de nos cas (Zaviacic, 1999; Zaviacic et al. 2000). Mais, l'examen systématique de tous les segments de l'urètre sur toute sa longueur, a toujours découvert au moins un canal et glande (para-urétrale).

Si on admet qu'une telle constatation équivaut à identifier une prostate, alors toutes les femmes en ont une, quelle que soit sa forme, même rudimentaire. Si on élimine les formes rudimentaires, on retrouvera au moins 90 % de femmes avec prostate

(Zaviacic, 1999; Zaviacic et al. 2000). Notre taux d'identification est plus élevé que chez d'autres auteurs; 66,7 % pour Wernert et al. (1992), 70 % chez Tepper et al. (1984), près de 80 % pour Pollen et Dreilinger (1984); Sesterhenn et al. (1998).

D'autres types – "moyen" ou en forme d'"haltère" – qui ont été décrits, n'ont probablement pas d'importance pratique. Leur fréquence est moins élevée que celle des autres types (Zaviacic, 1999; Zaviacic et al. 2000). Il faut encore une fois souligner que le type "antérieur (méatal)" est la configuration la plus fréquente (66 % avec CI 58-74 %). Les types méatal et postérieur (10 %) sont présents dans 3/4 de la population des femmes adultes (Zaviacic, 1999; Zaviacic et al. 2000).

La question du lieu d'abouchement des canaux de la prostate féminine reste toujours d'actualité. Les données recueillies à partir de l'examen de 250 malades de la Deuxième clinique gynécologique et obstétricale de Bratislava (en Slovaquie), ne permettent pas d'être d'accord avec Skene (1880), selon qui la prostate féminine est formée par deux canaux débouchant séparément à l'entrée de l'urètre féminin, ce qui est faussement mentionné jusqu'à présent dans la littérature anatomique générale (Rauber et Kopsch, 1929; Schaeffer, 1944; Moore, 1980; Williams et Warwick, 1980) ainsi que dans la littérature spécialisée en gyné-

cologie et en urologie (Kurman, 1994). A l'examen gynécologique et urologique, nous n'avons observé en aucun cas l'existence de canaux séparés de part et d'autres du méat urinaire. Selon notre expérience, c'est seulement chez quelques multipares, dont l'orifice urétral est élargi, que l'on peut voir – et seulement dans la lumière au début de l'urètre – de petits orifices des canaux de la grandeur de petits points. Selon nos observations, les canaux de la prostate féminine pénètrent dans la lumière urétrale, en arrière du méat de l'urètre et dans tout son trajet. C'est ainsi que l'avaient déjà formulé Huffman (1948) et après lui d'autres auteurs, dont nous mêmes, (Zaviacic et al. 1983, 1985; Zaviacic, 1987, 1999; Wernert et al. 1992). Des travaux cliniques qui corroborent ces dires, sont consacrés à l'uréthroplastie et à l'uréthrolyse externe, au traitement du syndrome urétral et à la correction de la résistance distale urétrale, causes de dysurie chez la femme (Richardson, 1969, 1972; Richardson et Stonington, 1969). Selon l'opinion de Skene (1880), les canaux de la prostate féminine débouchent séparément dans la vulve aux côtés du méat de l'urètre féminin.

Les canaux de la prostate féminine, comme chez l'homme, libèrent leur contenu à travers l'urètre par un mécanisme de sécrétion continue et au moment des expulsions urétrales (éjaculation) (Zaviacic et al. 1988). Chez l'homme, comme chez la femme, c'est par l'urètre que sont excrétées urine et sécrétion prostatique.

On a constaté la présence de cellules sécrétoires en microscopie électronique parmi les cellules des glandes prostatiques féminines (Zaviacic et al. 2000) comme dans les glandes de la prostate masculine (Fisher et Jeffrey, 1965; Brandes, 1974; Srigley et al. 1988). Leur cytoplasme apical contient des éléments sécrétoires nombreux (vacuoles et granules sécrétoires), un réticulum endoplasmique granuleux, un appareil de Golgi développé et des mitochondries nombreuses caractérisant une configuration sécrétoire active de ces cellules avec un type de sécrétion apocrine et mérocrine (Zaviacic et al. 2000). Entre les cellules sécrétoires et la membrane basale se trouvent des cellules basales (des réservoirs). Leur cytoplasme est dense avec un réticulum endoplasmique granulaire et des mitochondries

mais sans éléments sécrétoires (Zaviacic et al. 2000). En dehors de deux types de cellules prostatiques, on a aussi trouvé des cellules de transition placées entre les cellules basales et les cellules sécrétoires ou à proximité. La présence de cellules de transition confirme le rôle des cellules basales (rôle de réservoir) pour le renouvellement des cellules des glandes de la prostate féminine (Zaviacic et al. 2000) comme c'est le cas pour la prostate masculine (Xue et al. 1998). L'analyse ultrastructurale de la prostate féminine normale au microscope électronique de transmission, a montré que les glandes prostatiques d'une femme adulte présentent des cellules sécrétoires et basales morphologiquement mûres (Figure 3) (Zaviacic, 1999; Zaviacic et al. 2000).

Par des méthodes histochimiques différentes, on a pu prouver qu'il y avait dans les cellules sécrétoires des glandes de la prostate féminine une phosphatase acide spécifique (PSAP) de la prostate et des lysosomes comme dans la prostate de l'homme (Zaviacic, 1984). L'activité sécrétoire des cellules prostatiques féminines en fonction de la formation du liquide prostatique féminin s'appuie sur la preuve histochimique E-600 de l'estérase sensitive, du glucose-6-phosphatase et d'autres enzymes (Zaviacic, 1984). Les différences dans les activités de naphthyle estérase, glucose-6-phosphatase et quelques déshydrogénases de la prostate féminine, de l'âge de la procréation jusqu'après la ménopause, pourraient montrer qu'il y a une capacité fonctionnelle différente de la prostate pendant la vie d'une femme et une dépendance fonctionnelle éventuelle par rapport aux hormones sexuelles femelles (Zaviacic et al. 1989).

L'antigène spécifique prostatique (PSA) est aujourd'hui le marqueur le plus souvent utilisé pour identifier le tissu prostatique féminin normal et pathologiquement modifié (Pollen et Dreiling, 1984; Tepper et al. 1984; Wernert et al. 1992; Zaviacic et al. 1994; Zaviacic, 1997; Sloboda et al. 1998; Zaviacic et Ablin, 2000). Le PSA est immuno-histochimiquement localisé dans la couche apico-superficielle des cellules sécrétoires prostatiques féminines ainsi que dans les cellules uro-épithéliales d'autres secteurs du système génito-urinaire féminin (Figure 4) (Zaviacic et Ablin, 2000). Entre autres évidences, le concept non vestigial d'une prostate féminine est basé à présent sur la démonstration d'une anti-

généicité semblable entre la prostate de l'homme et les glandes para-urétrales de Skène, comme le montrent la positivité du PSA et du PSAP (phosphatase acide prostatique spécifique). L'expression d'antigènes hautement spécifiques à la prostate masculine justifie donc l'utilisation du terme de prostate chez la femme, comme cela est accepté par le FICAT.

Chez la femme, de même que chez l'homme, la prostate féminine représente la source essentielle de PSA (Zaviacic et al. 2000). Quand des tissus pathologiques produisent du PSA, la quantité de PSA sérique et urinaire est la somme de la production prostatique normale et extraprostatique anormale de ces tissus pathologiques, tant chez l'homme que chez la femme (Zaviacic, 1999; Zaviacic et al. 2000).

Conclusion

La recherche sur la prostate de la femme est passée de l'époque de Reijnier de Graaf (De Graaf, 1672) à la période de la conception vestigiale des glandes et des canaux de Skene para-urétraux dits "non-fonctionnels et sans importance" du fait du rôle controversé joué par le gynécologue américain Alexandre J.C. Skene (Skene, 1880),

à l'actuelle conception non-vestigiale de la prostate féminine; organe génito-urinaire fonctionnel féminin.

Cette période commence à partir de la fin des années quarante par des travaux d'Huffman (1948, 1951) et continue par des travaux du début des années quatre-vingt jusqu'à nos jours. C'est dans les cinquante dernières années qu'il y a eu plus particulièrement vingt années de recherche sur la prostate féminine, dont plusieurs résultats sont originaires de notre institut (Zaviacic 1984, 2001; Zaviacic and Whipple, 1993, 2001; Zaviacic et Ablin, 1998, 2000; Zaviacic et al. 2000) (Zaviacic, 1999).

A l'aube du troisième millénaire, la prostate féminine se présente comme un organe génito-urinaire à la structure définie, des paramètres ultrastructurels prostatiques inclus, avec une fonction exocrine et neuro-endocrine et une pathologie – donc avec des paramètres comparables avec la prostate masculine (Zaviacic, 1999).

RÉFÉRENCES

- 1- BRANDES D. (1974) *Fine structure and cytochemistry of male sex accessory organs*. In : Brandes D. *Male Accessory Sex Organs. Structure and Function in Mammals*. New York,

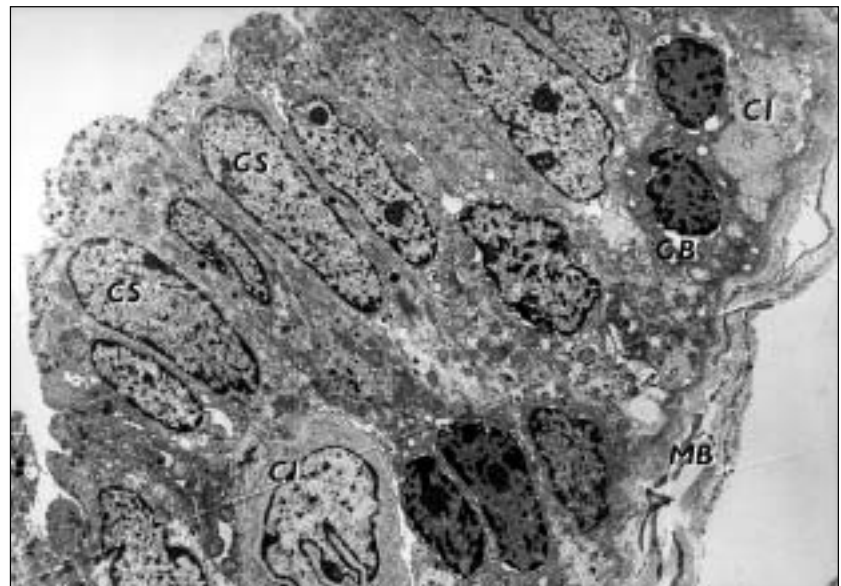


Figure 3 : Agrandissement de la prostate féminine normale. Les cellules basales (CB) se trouvent sur la membrane basale (MB), dans leur proximité on trouve une partie de la cellule intermédiaire (CI). La lumière de la glande est limitée par des cellules hautes sécrétoires cylindriques (CS). Dans leur partie supranucléaire se trouvent de nombreux éléments de sécrétion (vacuoles sécrétoires et granules sécrétoires). Dans la partie superficielle des cellules sécrétoires se trouvent des protubérances apicales avec vacuoles vides. Les noyaux des cellules sécrétoires, à la différence des cellules basales, contiennent des grands nucléoles et une chromatine dispersée. Uranyl acétate, lead citrate, x 10000.

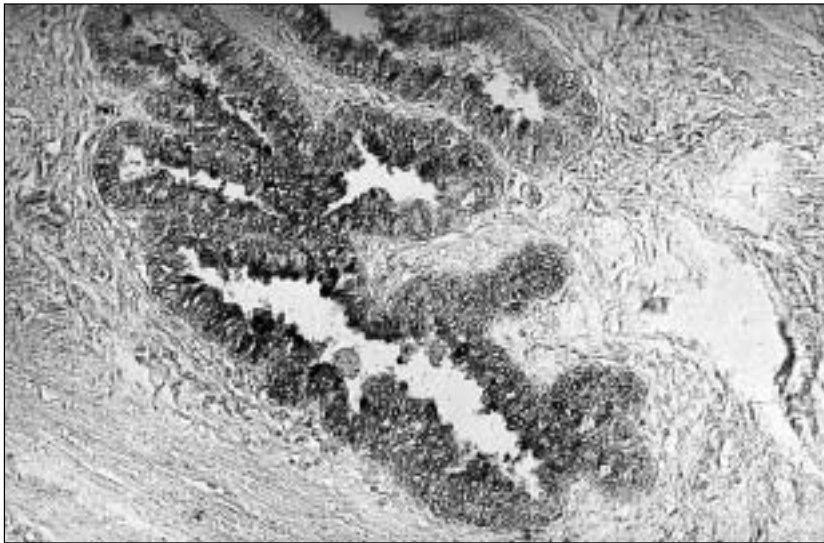


Figure 4 : Présence modérée ou élevée de PSA dans la partie apicale superficielle des cellules sécrétoires et dans les membranes des glandes prostatiques féminines. Technique de biotine-streptavidine-peroxydase. Une femme de 19 ans, x 180.

San Francisco, London, Academic Press.

- 2- CALDWELL G.T. (1941) *The glands of the posterior female urethra*. Texas State J. Med. 36 : 627-32.
- 3- CAMPBELL M. (1954) *Urology*. Philadelphia, Saunders.
- 4- DE GRAAF R. (1672) *De mulierum organis generationi inservientibus. Tractatus novus demonstrans tam homines et animalia caetera omnia, quae viviparaducuntur, haud minus quam vivipara ab ovo originem ducere*. Leyden.
- 5- DETER R.L., CALDWELL G.T., FOLSOM A.I. (1946) *A clinical and pathological study of the posterior female urethra*. J. Urol. 55 : 651-62.
- 6- EGLOFF B. (1972) *Pathologische Anatomie der weiblichen Urethra*. In : Lubarsch O., Henke F., Rössler R., Uehlinger E. *Handbuch der pathologischen Anatomie*. VII/4 Weibliche Geschlechtsorgane. Berlin, Heidelberg, New York, Springer Verlag.
- 7- EICHEL E.W. (1997) *Coital orgasm defined by the CAT research*. Abstract book of 13th World Congress Sexuality and Human Rights, Valencia, Spain, June 25-29.
- 8- EICHEL E.W., EICHEL J.D., KULE S. (1988) *The technique of coital alignment and its relation to female orgasmic response and simultaneous orgasm*. J. Sex Marit. Ther. 14 : 129-141.
- 9- EVATT E.J. (1911) *A contribution to the development of the prostate gland in the human female and a study of the homologues*

of the urethra and vagina of the sexes. J. Anat. Physiol. 45 : 122-30.

- 10- FISHER E.R., JEFFREY W. (1965) *Ultrastructure of human normal and neoplastic prostate with comments relative to prostatic effects of hormonal stimulation in the rabbit*. Amer. J. Clin. Path. 44 : 119-34.
- 11- FOLSOM A.I., O'BRIEN H.A. (1943) *The female obstructing prostate*. JAMA; 121 : 573-80.
- 12- FOLSOM A.I., O'BRIEN H.A. (1945) *The female urethra. The connecting link between the urologist and the gynecologist*. JAMA; 128 : 408-14.
- 13- GRÄFENBERG E. (1950) *The role of the urethra in female orgasm*. Int. J. Sexol. 3 : 145-48.
- 14- HUFFMAN J.W. (1948) *The detailed anatomy of the paraurethral ducts in the adult human female*. Amer. J. Obstet. Gynecol. 55 : 86-101.
- 15- HUFFMAN J.W. (1951) *Clinical significance of the paraurethral ducts and glands*. Arch. Surg. 62 : 615-26.
- 16- JOCELYN H.D., SETCHELL B.P., DE GRAAF R. (1972) *On the human reproductive organs. An annotated translation of tractatus de virorum organis generationi inservientibus (1668) and the mulierum organis generationi inservientibus tractatus novus (1672). New treatise concerning the generative organs of women*. J. Reprod. Fert. 17 ; (Supplement) : 77-222.
- 17- JOHNSON F.P. (1922) *Homologue of the prostate in the female*. J. Urol. 8 : 13-34.
- 18- KORENCHEVSKY V. (1937) *The female*

prostate gland and its reaction to the male sexual compounds. J. Physiol. 90 ; 371-76.

- 19- KURMAN J. (1994) *Blaustein's Pathology of the Female Genital Tract*. (4th Ed). New York, Springer Verlag.
- 20- LADAS A.K., WHIPPLE B., PERRY J.D. (1982) *The G-Spot and Other Recent Discoveries about Human Sexuality*. New York, Holt, Rinehart and Winston.
- 21- MALLON R.B. (1983) *Prostatic tissue in females (Letter)*. J. Sex. Educ. Ther. 9 ; 6.
- 22- MOORE K.L. (1980) *Clinically Oriented Anatomy*. Baltimore, London, W. Wilkins Co.
- 23- PERRY J.D., WHIPPLE B. (1981) *Pelvic muscle strength of female ejaculators : Evidence in support of a new theory of orgasm*. J. Sex. Res. 17 ; 22-39.
- 24- PETERSEN R.O. (1994) *The urinary tract and male reproductive system*. In : RUBIN E., FARBER J.L. *Pathology*, 2nd ed. Philadelphia, J.B. Lippincott.
- 25- PETROWA E.M., KARAEWA C.S., BERKOWSKAJA A.E. (1939) *The structure of the female urethra*. Arch. Gynec. 163 ; 343-57.
- 26- POLLEN J.J., DREILINGER A. (1984) *Immunohistochemical identification of prostatic acid phosphatase and prostate specific antigen in female periurethral glands*. Urology ; 23 : 303-04.
- 27- RAUBER A., KOPSCH F. (1929) *Lehrbuch und Atlas der Anatomie des Menschen*. Leipzig, Georg Thieme Verlag.
- 28- RICHARDSON F.H. (1969) *External urethroplasty in women : Technique and clinical evaluation*. J. Urol. 101 ; 719-23.
- 29- RICHARDSON F.H. (1972) *External urethroplasty for treatment of the urethral syndrome in the female*. Br. J. Urol. : 44 ; 125.
- 30- RICHARDSON F.H., STONINGTON O.G. (1969) *Urethrolisis and external urethroplasty in the female*. Surg. Clin. North. Amer. 49 ; 1201-08.
- 31- SCHAEFFER J.P. (1944) *Morris Human Anatomy. A Complete Systematic Treatise*. Philadelphia, The Blakiston.
- 32- SESTERHENN I.A., DAVIS C.J. Jr, MOSTOFI F.K. (1998) *Benign prostate, prostatic hyperplasia and prostatic carcinoma in female patients*. Mod. Pathol. 11 ; 95 A.
- 33- SKENE A.J.C. (1880) *The anatomy and pathology of two important glands of the female urethra*. Amer. J. Obstet. Diss Women Child, 13 ; 265-70.
- 34- SLOBODA J., ZAVIACIC M., JAKUBOVSKY J., HAMMAR E., JOHNSON J. (1998) *Metastasizing adenocarcinoma of the female prostate (Skene's paraurethral glands)*.

- Histological and immunohistochemical prostate markers studies and first ultrastructural observation.* Path. Res. Pract. 194 : 129-36.
- 35- SRIGLEY J.R., HARTWICK W.J., EDWARDS V., DE HARVEN E. (1988) *Selected ultrastructural aspects of urothelial and prostatic tumours.* Ultrastruct. Pathol. 12; 49-65.
- 36- STIFTER K.F. (1988) *Die dritte Dimension der Lust. Das Geheimnis der weiblichen Ejakulation.* Frankfurt/Main, Berlin, Ullstein.
- 37- TEPPER S. L, JAGIRDAR J., HEATH D., GELLER S.A. (1984) *Homology between the female paraurethral (Skene's) glands and the prostate.* Arch. Path. Lab. Med. 108; 423-25.
- 38- THACKRAY A.C. (1978) *The male reproductive organs.* In: Symmers W.St.C. Systemic Pathology, 2nd ed. Vol. 4. Edinburgh, London, New York, Churchill Livingstone.
- 39- WERNERT N., ALBRECHT M., SESTERHENN I., GOEBBELS R., BONKHOFF H., SEITZ G., INNIGER R., REMBERGER K. (1992) "The female prostate": Location, morphology, immunohistochemical characteristics and significance. Eur. Urol. 22; 64-9.
- 40- WILLIAMS P.L., WARWICK R. (1980) *Gray's Anatomy.* Edinburg, London, Melbourne, New York, Churchill Livingstone.
- 41- XUE Y., SMEDTS F., VERHOFSTAD A., DEBRUYNE F., DE LA ROSETTE J., SCHALKEN J. (1998) *Cell kinetics of prostate exocrine and neuroendocrine epithelium and their differential interrelationship: new perspectives.* Prostate Suppl. 8 : 62-73.
- 42- ZAVIACIC M. (1984) *Enzyme histochemistry of the adult human female prostate: hydrolase and dehydrogenase distribution.* Cell. Molec. Biol. 30 : 537-43.
- 43- ZAVIACIC M. (1984) *Enzyme histochemistry of the adult human female prostate: acid phosphatase distribution.* Cell. Molec. Biol. 30; 545-61.
- 44- ZAVIACIC M. (1987) *The female prostate: Nonvestigial organ of the female. A reappraisal.* (Letter to the Editor). J. Sex Marit. Ther. 13; 148-52.
- 45- ZAVIACIC M. (1997) *Prostate-specific antigen and history of its discovery.* Bratisl. Lek. Listy, 98 : 659-62.
- 46- ZAVIACIC M. (1999) *The Human Female Prostate. From Vestigial Skene's Paraurethral Glands and Ducts to Woman's Functional Prostate.* Bratislava, SAP, 1sted. (le livre + CD).
- 47- ZAVIACIC M. (2001) *The human female prostate and its role in woman's life: sexology implications.* Scand. J. Sexol. 4 : 199-211.
- 48- ZAVIACIC M., WHIPPLE B. (1993) *Update on the female prostate and the phenomenon of female ejaculation.* J. Sex. Res. 30 : 148-51.
- 49- ZAVIACIC M., ABLIN R.J. (1998) *The female prostate* (Correspondence). J. Natl. Cancer Inst. 90 : 713.
- 50- ZAVIACIC M., ABLIN R.J. (1998) *Letter to the Editor.* J. Urol. 160 : 1441.
- 51- ZAVIACIC M., ABLIN R.J. (2000) *The female prostate and prostate-specific antigen. Immunohistochemical localization, implications of this prostate marker in women and reasons for using the term "prostate" in the human female.* Invited Review. Histol. Histopathol. 15 : 131-42.
- 52- ZAVIACIC M., WHIPPLE B. (2001) *Female ejaculation, female prostate and female sexuality: specific components of female gender biology.* Sexuologia/Sexology; 1 : 12-18 (in: Slovak, Summary in English).
- 53- ZAVIACIC M., BROZMAN M., HOLOMAN I.K., ZAVIACICOVA A., OBERUCOVA J. (1983) *New information on the paraurethral (Skene's) ducts and glands in the female.* Bratisl. Lek. Listy, 79 : 533-44 (in: Slovak, Summary in English).
- 54- ZAVIACIC M., BROZMAN M., ZAJICKOVA M., BLAZEKOVA J., OBERUCOVA J. (1985) *The adult human female urethra. Enzyme-histochemical study.* Acta Histochem. 77 : 165-75.
- 55- ZAVIACIC M., ZAVIACICOVA A., BROZMAN M., HOLOMAN I. K., BRUCHAC D., OBERUCOVA J., KOKAVEC M. (1985) *The female prostate or Skene's paraurethral glands and ducts? Reasons for returning to the original term of de Graaf.* Cs. Gynecol. 50; 372-77 (in: Slovak).
- 56- ZAVIACIC M., ZAVIACICOVA A., HOLOMAN I.K., MOLCAN J. (1988) *Female urethral expulsions evoked by local digital stimulation of the G-spot: Differences in the response patterns.* J. Sex. Res. 24 : 311-18.
- 57- ZAVIACIC M., HOLOMAN I.K., MOLCAN J., ZAVIACICOVA A. (1988) *Weibliche Ejakulation klinisch provoziert.* Sexualmedizin; 17 : 196-200.
- 58- ZAVIACIC M., PORUBSKY J., VIERIK J., HOLOMAN I.K. (1989) *Enzymic equipment of the prostate in women of child-bearing age and women after menopause. Comparative histochemical study.* Cs. Gynecol. 54 : 755-60 (in: Slovak).
- 59- ZAVIACIC M., RUZICKOVA M., JAKUBOVSKY J., DANIHEL L., BABAL P., BLAZEKOVA J. (1994) *The meaning of prostatic markers in orthology of the female prostate.* Bratisl. Lek. Listy; 95 : 491-97 (in Slovak, Summary in English).
- 60- ZAVIACIC M., RUZICKOVA M., BLAZEKOVA J., ZAVIACIC T., ITOH Y., OKUTANI R., KAWAI T. (1997) *Immunohistochemical distribution of rabbit polyclonal antiurinary protein 1 antibody in the female (Skene's gland) and male prostate: new marker for neuroendocrine cells?* Acta Histochem. 99 : 267-75.
- 61- ZAVIACIC M., ABLIN R.J., RUZICKOVA M., STVRTINA S., DANIHEL L., ZAVIACIC T., POHLODEK K., HOLOMAN K. (1999) *The normal female and the male breast epithelium do not express prostate-specific antigen. Preliminary immunohistochemical observations of autopsy breast tissues.* Gen. Physiol. Biophys. 18; Suppl. 1 : 41-4.
- 62- ZAVIACIC M., ZAJICKOVA M., BLAZEKOVA J., DONAROVA L., STVRTINA S., MIKULECKY M., ZAVIACIC T., HOLOMAN I.K., BREZA J. (2000) *Weight, size, macro-anatomy and detailed histology of the normal prostate in the adult human female: A minireview.* J. Histotechnol. 23 : 61-9.
- 63- ZAVIACIC M., ABLIN R.J., RUZICKOVA M., STVRTINA S., GALBAVY S., DANIHEL L., POHLODEK K., ZAVIACIC T., HOLOMAN K. (2000) *Immunohistochemical study of prostate-specific antigen in normal and pathological human tissues with special reference to the male and female prostate and breast.* J. Histotechnol. 23; 105-11.
- 64- ZAVIACIC M., JAKUBOVSKA V., BELOSOVIC M., BREZA J. (2000) *Ultrastructure of the normal adult human female prostate gland (Skene's gland).* Anat. Embryol. 201 : 51-61.

Milan Zaviacic* ; Tomas Zaviacic ;
Richard J. Ablin*** ; Jan Breza**** ;
Karol Holoman****

*Institut d'anatomie pathologique.

**Deuxième clinique gynécologique et obstétricale de la Faculté de médecine de l'Université Comenius et Centre hospitalier universitaire (CHU), Bratislava, République slovaque.

***Innapharma, Park Ridge, New-Jersey, États-Unis.

****Clinique urologique de la Faculté de médecine de l'UC et Hôpital de Dérier, Bratislava, République slovaque.

Pr Milan Zaviacic,

Docteur en sciences,

Chef de l'Institut de pathologie,

Faculté de médecine,

Université Comenius,

Sasinkova 4, 81108 Bratislava,

République slovaque

E-mail : zaviacic@fmed.uniba.sk



M. ZAVIACIC ; T. ZAVIACIC ;
R.J. ABLIN ; J.BREZA ;
K. HOLOMAN

SUMMARY : Reinier de Graaf, a Dutch physiologist and histologist, was the first to describe the female prostate and to assign it this term and was also the first who attempted to formulate the function of this female organ. Description of the American gynecologist Alexander J.C. Skene became the subject of considerable debate increasing lack of attention and importance to the female prostate in spite of the elegant studies of the American gynecologist Huffman. At the beginning of 20th century the female prostate was referred to as Skene's para-urethral ducts and glands, as an insignificant rudimentary vestigial organ without any importance in the life of women. The expression of the prostate-specific antigen in female Skene's para-urethral glands and ducts and structural and functional parameters and diseases similar to that of the male prostate have provided convincing evidence for the existence of the prostate in women. *Federative International Committee on Anatomical Terminology (FICAT)* at the 2001 meeting at Orlando, FL, USA has agreed to mention the term female prostate (*prostata feminina*) in the new forthcoming edition of *Histology Terminology*. This decision prohibits further use of the terms of paraurethral glands and ducts, or Skene's glands for designation of prostate in the human female. The contemporary research presents the female prostate as an organ with inferior parameters (weight, size, functional productivity) if compared with the male prostate, similarly to many other organs in man. Its average weight is 5.2 g, representing 1/5 to 1/4 of the weight of an adult male prostate. The female prostate is situated in the wall of the urethra that limits its size and weight. Despite the smaller space, its cellular equipment furnishes exocrine function (production of female prostatic fluid) and neuroendocrine function. Equally to the male prostate, glands, ducts and smooth muscle cells (muscle-fibrous tissue) form the female prostate. The structure, including the ultrastructure of secretory (luminal), basal (reserve) and intermediary cells of the female prostate glands, corresponds to the structure of the same cells in glands of the prostate of an adult male. Also the function of these cells is the same as in the male prostate. Both, the basal cells and from them derived intermediary cells, take part in the renewal of exocrine (secretory) cells of the female prostate glands. (Immuno) histochemistry proved activity of lysosomal and prostate-specific acid phosphatase (PSAP) and disclosed the expression of prostate-specific antigen (PSA) in the luminal-apical part of the secretory cells of the female prostate. The expression of the highly specific antigen of the male prostate in this female structure implies the necessity to use the unambiguous term "prostate" also in women. This excludes the Skene's eponym (Skene's glands) or the histological descriptive term "paraurethral glands and ducts", still nowadays incorrectly used by some to identify the female prostate. The terminology decision of FICAT with introducing the term "*prostata feminina*" respects the novel data achieved in the research of the female prostate.

The female prostate: history, functional morphology and sexology implications

**Federative International Committee on Anatomical Terminology (FICAT)* at the 2001 meeting at Orlando, FL, USA has agreed to mention the term female prostate (*prostata feminina*) in the new forthcoming edition of *Histology Terminology*. This decision prohibits further use of the terms of paraurethral glands and ducts, or Skene's glands for designation of prostate in the human female.

**Parts of this paper have been presented as an Invited Lecture on 15th World Congress of Sexology, Paris, June 24-28, 2001.

Milan Zaviacic, MD, PhD, DSc is professor of pathology and forensic medicine at the Comenius University Bratislava, Slovak Republic (Slovakia). The results of Pr Zaviacic's research activities have so far been presented in 440 lectures and up to 550 various scientific publications, including full papers (245), editorials, research reports, review articles, book chapters and contributions to proceedings of scientific congresses, symposia and conferences (40 of them concerning different aspects of the female prostate). Professor Milan Zaviacic has established the updated non-vestigial concept of the prostate in the female. Based on multidisciplinary research, he has presented the female prostate as a functional genitourinary organ in the female with a specific structure, function and pathology. He has shown that the female prostate parameters are similar or even identical with those of the adult male prostate. This recent concept has been based on morphological, histochemical, forensic-medical, sexological, gynecological, urological, chronobiological and pathology research. Professor Zaviacic is member of the Advisory Council Board of the *European Society of Pathology (ESP)*, member of the National Committee of the *Slovak Society of Pathologists*, member of the National Committee of the *Slovak Sexology Society*, Vice-President of the *Slovak Society of Histochemistry and Cytochemistry*, and elected member of *International Academy of Sex Research (IASR)*.

History

As early as in 1672, De Graaf presented the first description of the female prostate and he was also the first to use this term (De Graaf, 1672). In his work *De mulierum organis generationi inseruientibus...* Reinier De Graaf (1641-73), a Dutch physiologist and histologist, described one year before his death the structure of the female prostate amazingly exactly for his period of time as being formed by glands and ducts around the female urethra. De Graaf was also the first to attempt to formulate the role of the female prostate on writing "The function of the prostate (*corpus glandulosum*) is to generate a pituitoserous juice which makes women more libidinous with its pungency and saltiness and lubricates their sexual parts in agreeable fashion during coitus (Jocelyn et al. 1972)". Although De Graaf's idea on the homology of the female para (urethral) glands and ducts with the male prostate was basically but of intuitive

nature, nevertheless he is undoubtedly the discoverer of the female prostate.

The American gynecologist Alexander J.C. Skene (1838-1900) played a rather controversial role in the problem of the female prostate. His idea, voiced 200 years after de Graaf and identifying the female prostate with two paraurethral ducts (two important glands of the female urethra) opening on the sides of the urethral orifice (Skene, 1880), has exerted an inhibitory effect on further advances in the problem of the female prostate, and that despite the fact that dating back as many as 50 years, Huffman expressed his disagreement with several conclusions drawn by Skene (Huffman, 1948, 1951). Even to date, the female prostate is known to many urologists (gynecological urologists) and gynecologists under Skene's name.

In the past, the problem of the female prostate interested such authorities in medicine and biology as Astruc (1737), Virchow (1853) and several others, as presented by Huffman (1948) and later

by Stifter (1988). It has to be emphasized that the epoch of the great pathologist Rudolf Virchow (1821-1902) was rather supportive of the study of the female prostate and Pr. Virchow himself considered it to be a genitourinary organ of the female in its own right, to which he gave his considerable attention. He was first to describe in the glands of the female prostate concretions "*corpora amy-lacea*", which had before been known to occur only in the male prostate. Despite the great interest and the favorable attitude of Rudolf Virchow and of his time towards this field of study, there was no breakthrough in the research into the problem of the female prostate since at that time autopsy and macrodiagnostics were predominant in pathology, while biopsy and histological methods were in research activities rather at their beginning. Yet the outstanding scientific authority of Prof. Virchow promoted the study of the female prostate for many years even after his death. The clinical interest in the female prostate was at that time and also later on less intensive than that of morphologists.

At present we witness an increasing interest of urologists and gynecologists in the female prostate, associated to a great deal with the new information on the female prostate-specific antigen and its potential implications in the female. Similarly as the prostate in the male, the female prostate is considered to be the main producer of this prostatic marker in the woman (Zaviacic and Ablin, 1998, 2000). The lack of clinical interest may be accounted for by the fact that compared to the male prostate, the female prostate is far less affected by diseases, and those which do occur are usually of minor severity. As yet, however, exact clinico-pathological data on diseases of the female prostate and on their actual incidence are not available.

The term female prostate was commonly used till the beginning of the 20th century. At that time the term was based mainly on embryological data showing that Skene's glands and the male prostate arise from the same embryonic primordium, the urogenital sinus. Even to date, many textbooks

present these embryological findings as the sole argument in favor of the homology between Skene's glands (female prostate) and the male prostate (Campbell, 1954; Egloff, 1972; Kurman, 1994). Unfortunately, and apparently justifiably, for the majority of scientists embryological findings supporting the notion of homology of the two genitourinary structures have been insufficient for accepting unequivocally the existence of the prostate in the woman.

On the other hand, from the early years of our century, we can trace an opposite trend considering the female prostate referred to as Skene's para-urethral ducts and glands as an insignificant, rudimentary, vestigial female organ, which does not play any role in the life of the woman. The vestigial concept of the female prostate has been based mainly on gross macroscopic differences between the size of the prostatic glands in the two genders. The difference in size, in disfavor of the female prostate, provided for many a welcome implication that it would be unable to function, or at least to function comparably to the male prostate. On the other hand, the female prostate was considered to be clinically rather unproblematic and this notion has apparently supported the vestigial concept, though even this favored and often repeated statement fails to be based on objectively established evidence. The male prostate presents a classical example of an androgen-dependent organ, while the question whether, and if then to what extent is the function of the female prostate hormonally dependent has not been fully answered as yet. Nevertheless, our first electron microscopic study of the ultrastructure of the normal female prostate indicated that in the function of the female prostate and particularly in its secretory cells, estrogens may play an equally significant role (Zaviacic et al. 2000) as do androgens in the maturation and function of the male prostate. In urologists, endocrinologists and gynecologists, this assumption should stimulate a greater interest in studying the relationship between the female prostate and sex hormones, which has so far received

but little attention, and even that goes as far back as the late 30's (Korenchevsky, 1937).

The history of the study of the female prostate extending from the vestigial position to the present-day non-vestigial concept developing since the early 80s was treated of in our previous publications which presented evidence on the unequivocally non-vestigial position of the female prostate. Attention of those interested in this topic should be directed especially to the DSc Thesis of the first author of this review and a number of earlier publications (Zaviacic, 1984; 1987; Zaviacic and Whipple, 1993; Zaviacic et al. 1983, 1985) as well as some recent ones (Zaviacic and Ablin 1998, 2000; Zaviacic, 1999, 2001; Zaviacic and Whipple, 2001; Zaviacic et al. 2000). A historically broadly conceived overview on the female prostate and its function in the female ejaculation phenomenon, along with different attitudes on female ejaculation as observed in individual sex cultures, including those of ancient India and Japan, can be found in Stifter's work (Stifter, 1988).

Huffman's publications (Huffman, 1948, 1951) provide important data concerning specifically the orthology and pathology of the female prostate but dealing also with historical aspects. Earlier studies, dating back to the first half of the 20th century, deserve also to be mentioned (Evatt, 1911; Johnson, 1922; Korenchevsky, 1937; Petrowa et al. 1939; Caldwell, 1941; Folsom and O'Brien, 1943; 1945; Deter et al. 1946). They have contributed to the gradual shaping of views on this female organ and influenced Huffman's conclusions with their lasting impact on the problem of the female prostate.

The present intensive research on the female prostate, which started in the early 80's, has succeeded in presenting this small organ of the genitourinary system of the woman as an organ with defined structure and function. Ever more morphological and clinical parameters keep accumulating which are shown to be identical or at least well comparable with those of the male prostate.

In pathology, the main focus is on car-

cinoma, benign hyperplasia and inflammation of the female prostate. The value of several prostatic markers and especially of prostate-specific antigen (PSA) in the study of the normal and pathologically changed prostate is being emphasized. Further updated findings concern clinical, sexological, forensic-sexological, gynecologic-urological, chronobiologic and forensic-medical aspects.

The intensive research and publication activities in the last two decades have affected our opinion on this organ, as documented by different views of the same authors expressed in publications that appeared within a relatively short period of time (Wernert et al. 1992, Sesterhenn et al. 1998). We are confident that such shifts in opinion occurred also due to the considerable influence of our numerous studies on the female prostate published over the last 20 years, as well as our recent contributions published with Dr. R. J. Ablin, PhD, discoverer of PSA (Zaviacic, 1997; Zaviacic et al. 1994). These contributions appeared in *Correspondence* of the *Journal of the National Cancer Institute*

(Zaviacic and Ablin, 1998), in *Letter to the Editor* of the *Journal of Urology* (Zaviacic and Ablin, 1998), in the *Invited Review* in the *Journal of Histology and Histopathology* (Zaviacic and Ablin, 2000).

Macroanatomy, functional morphology and sexology implications of the female prostate

While the male prostate surrounds the urethra, the female prostate (Figure 1) lies in the wall of the female urethra (Huffman 1948; Zaviacic et al. 1983, 2000; Wernert et al. 1992). This is the basic macroscopic difference between the male and female prostate glands. The thickness of the wall and the length of the female urethra thus limit the size of the prostate, which for these reasons is smaller than the prostate in the male. Nevertheless, despite the smaller space available for the female prostate, it possesses all the structural

components characteristic of the male prostate (Zaviacic, 1987, 1999).

The mean weight of the prostate of the adult female is 5.2 g and its size is 3.3 cm (length) x 1.9 cm (width) x 1.0 cm (height) (Zaviacic et al. 2000). If we consider the meatal type, the most frequent type of the female prostate occurring in approximately 70 % of adult women and presenting the greatest amount of prostatic tissue in the distal half of the female urethra (Figure 2), then the weight of the female prostate would vary within the range of 2.6 to 5.2 g (Zaviacic et al. 2000; Zaviacic, 1999) and represent roughly one tenth to one fifth or one quarter of the mean weight (23,7 g) of the adult male prostate (Thackray, 1978; Williams and Warwick 1980; Petersen, 1994).

Meatal type of the female prostate does not correspond to the topological placement of G-spot, which projects to the area of the posterior urethra and the neck of the urinary bladder. Only in 10 % of females, the majority of prostatic tissue was localized in this area (posterior type of the female prostate, Zaviacic, 1987; Zaviacic et al. 2000) and this type correspond to the place of G-spot. Eichel (1997), Eichel et al. (1988) pointed out the importance of the meatal type of the female prostate for achieving coital orgasm in the female when the anterior portion of the female urethra with the greatest amount of prostatic tissue is directly stimulated by pressure and counterpressure of the genital regions of the male and female. Eichel, thus turned our attention to the vaginal introitus where the urethral meatus and onset of the anterior urethra are projected.

The female prostate possesses histologically the same structures as the prostate of the male, i.e. glands, ducts, and smooth musculature. The ducts are more numerous than the glands and they exceed in number also the ducts in the male prostate. The smooth musculature (musculofibrous tissue) are also more abundant in the female compared to the male prostate (Zaviacic, 1987, 1999; Zaviacic et al. 2000). The prostatic (paraurethral) ducts do not open into the vulva on the sides of the meatus of the female

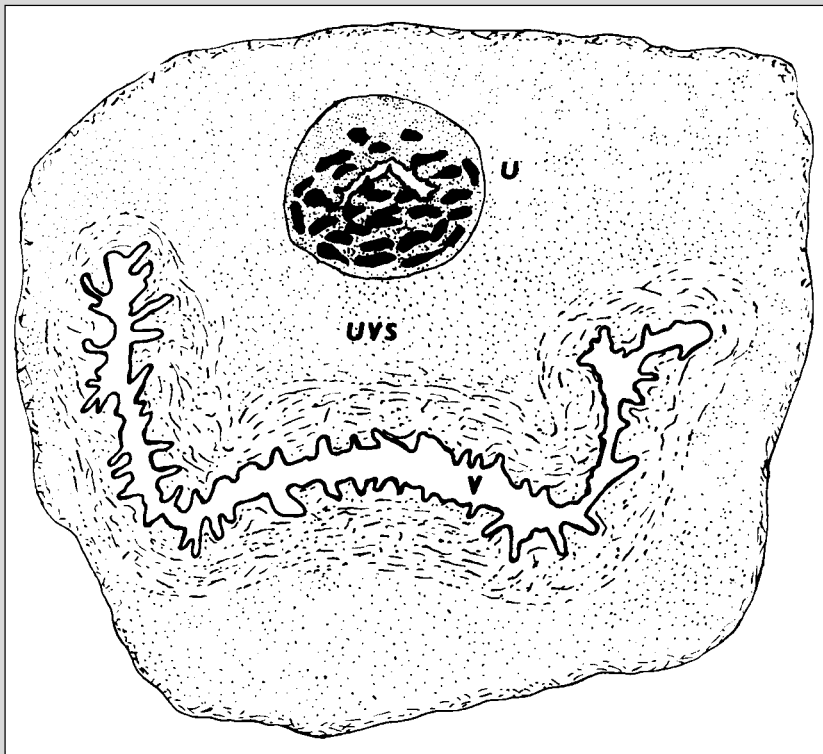


Figure 1 : The female prostate in the wall of the female urethra (U). The relationship is shown between the female urethra with the prostatic tissue, the urethro-vaginal septum (UVS) and the vaginal canal (V).

urethra, they rather penetrate into the lumen of the urethra along its whole length (Huffman, 1948; Zaviacic, 1999; Zaviacic et al. 2000), and it is through the urethra and not through separate openings that the female prostate discharges its contents (Zaviacic, 1999; Zaviacic et al. 2000).

Similarly as the prostate in the male, the female prostate has at least two main functions : exocrine – production of female prostatic fluid – and neuroendocrine function (Zaviacic, 1999). The exocrine function of the female prostate is reflected by its particular structure, including the presence of secretory and basal cells with their characteristic ultrastructural appearance. Tall cylindrical secretory (luminal) cells are the predominant type both in the female and male prostatic glands. Apical cytoplasm contains abundant secretory elements (secretory vacuoles and granules), rough endoplasmic reticulum, developed Golgi complexes and numerous mitochondria. These organelles characterize the active secretory configuration of female prostatic secretory cells with apocrine (apical blebs) and merocrine (secretory vacuoles and granules) type of secretion. Basal (reserve) cells were seen to be located between the secretory cells and the basement membrane. Their ground cytoplasm is dense with rough endoplasmic reticulum and mitochondria, without secretory elements. Their nuclei, unlike those of secretory cells, possess more peripheral condensed chromatin, dense dispersed chromatin, and sporadic nucleoli (Zaviacic, 1999; Zaviacic et al. 2000).

Besides the two basic types of mature prostatic cells there are also intermediary cells, located between the basal and secretory cells or in their close vicinity. Their cytoplasm exhibits numerous profiles of rough endoplasmic reticulum and free ribosomes. Secretory granules are practically absent (type 1 intermediary cells), so that they resemble basal (reserve) cells. In some of them, however, similarly as in secretory cells, secretory elements do appear (type 2 intermediary cells). The finding of intermediary cells supports the assumed function of basal (reserve) cells in the renewal of cells in




Figure 2 : "Anterior (meatal)" type of the female prostate according to Huffman's wax model (1948).

the female prostate glands, comparably to the role played by intermediary cells in the male prostate. Ultrastructural analysis of the normal female prostate performed by transmission electron microscopy confirmed that, similarly as in the postpubertal male, the prostatic glands in the adult female display morphologically mature secretory and basal cells (Figure 3) (Zaviacic, 1999 and references therein; Zaviacic et al. 2000).

Like in the male also in the female prostate, especially in its lumenally located secretory cells, lysosomal and prostatic (specific) acid phosphatase was determined histochemically using Gomori's, azo-coupling and Serano's methods (Zaviacic, 1984). Histochemical demonstration of E-600 sensitive esterase and glucose-6-phosphatase with further enzymes indicates secretory activity of female prostatic cells. These enzymes involved in proteosynthesis participate in the production of female prostatic fluid (Zaviacic, 1984). Concerning the spectrum of the enzymes determined, the enzyme equipment of the male and female prostate is comparable. Differences were however observed in the activity of some prostatic enzymes (naphthyl esterase, glucose-6-phosphatase, some dehydrogenases) in

women of childbearing age compared to women after menopause, potentially indicative of a varying functional capacity of the prostate in the course of woman's life (Zaviacic et al. 1989). Prostate-specific antigen (PSA) is currently the most frequently used marker for identification of normal and pathologically altered prostatic tissue in the female (Pollen and Dreilinger, 1984; Zaviacic et al. 1994; Zaviacic, 1997, 1999; Zaviacic and Ablin, 2000). Immunohistochemically, PSA is expressed in the highly specialized apically-superficial layer of female secretory cells of the prostate as well as in uroepithelial cells at other sites of the female urogenital tract (Figure 4) (Zaviacic, 1999). In clinical practice, PSA is a valuable marker in diagnosis and monitoring of diseases of the female prostate, particularly carcinoma. Besides other evidence, the non-ves-tigial concept of the female prostate is at present based on the demonstration of similar antigenicity between the male prostate and Skene's para-urethral glands, as evidenced by PSA and prostate-specific acid phosphatase (PSAP) positivity. Expression of the highly specific male prostate antigen in Skene's glands justifies by itself the use of the term prostate in the female, at present accepted by

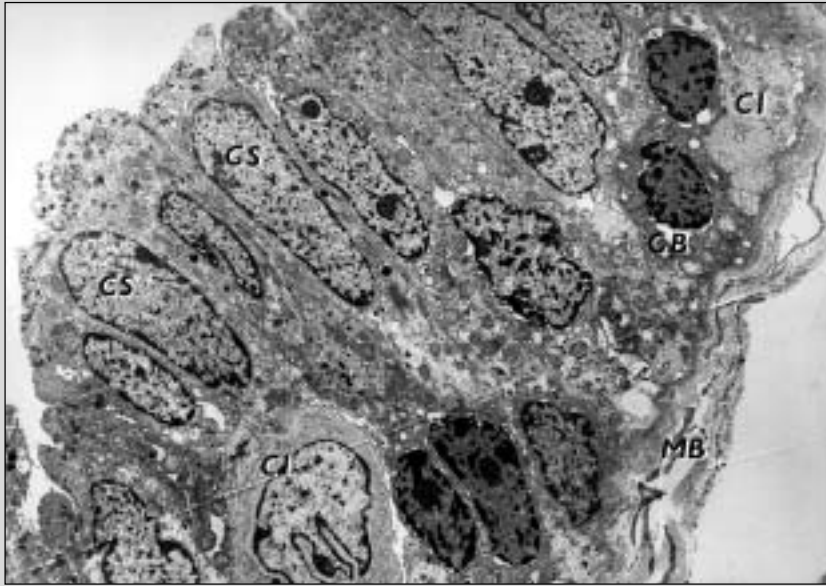


Figure 3 : Magnified overview of a normal gland of the female prostate. Basal cells (BC) rest on the basement membrane (MB). In the lower part a portion of an intermediary cell (CI). The lumen of the gland is lined with tall cylindrical secretory cells (CS) containing secretory vacuoles and secretory granules. Protuberances of the apical part of CS contain empty vacuoles. Uranyl acetate and lead citrate, x 10 000.

FICAT (see title page). Considering the immunohistochemical PSA expression in different female tissues samples it is evident that in the female, similarly as in the male, the prostate is the principal source of PSA (Zaviacic et al. 1999, 2000). With respect to pathological breast tissue, and/or other pathological tissues known to produce PSA, the total amount of PSA in serum and urine is the summation of the pro-

duction by the normal prostatic and the anomalous extraprostatic pathological tissue in the male and female patient (Zaviacic et al. 2000).

For neuroendocrine production, the female prostate is richly equipped with neuroendocrine cells, especially in the lining of prostatic ducts. In the male, the range of hormonal polypeptides produced by neuroendocrine cells of the prostate is well known. In the

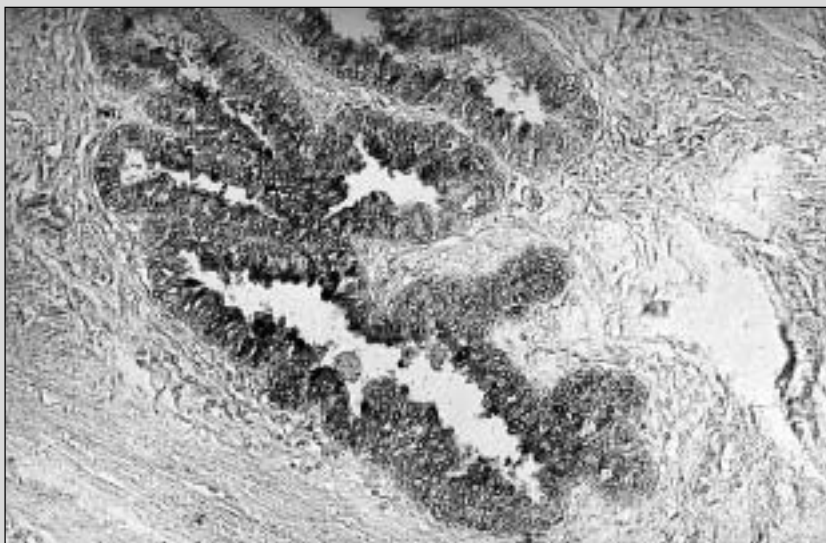


Figure 4 : Expression of prostate-specific antigen (PSA) in the apical part of cytoplasm of the secretory cells and in membranes of female prostatic glands. 19 years-old female, biotin-streptavidin-peroxidase technique, x 180.

female, however, immunohistochemically only the production of serotonin by female prostatic neuroendocrine cells has so far been established. To date we are but at the beginning in the study of the female prostate as a further neuroendocrine organ, a constituent part of the diffuse neuroendocrine system of the woman (Zaviacic, 1999 and references therein; Zaviacic et al. 1997).

Our insight into the exocrine function of the female prostate in producing female prostatic fluid is much more developed than our knowledge on its neuroendocrine function. It is true that pure prostatic fluid has not yet been isolated and it has been studied only as a component of the female ejaculate, whose substantial component it actually is. Nevertheless, important features of the biological phenomenon of female ejaculation and of the fluid of urethral expulsions (female ejaculate) have been gradually revealed, which appear to have implications for a variety of medical disciplines (Zaviacic, 1999 and references therein). Morphologically, the female ejaculate was found to be produced by cellular, mucinous, and urinary components. The cellular component of the female ejaculate is formed by squamous cells of the vaginal type, originating mainly from the lining of the female urethra and large prostatic (paraurethral) ducts (Zaviacic, 1999, 2001). On biochemical analysis, the fluid of urethral expulsions (female ejaculate) was found to have a significantly higher concentration of components arising from the female prostate, namely prostatic acid phosphatase and especially prostate-specific antigen, and a significantly lower concentration of urea and creatinine than urine specimens taken from the same women (Zaviacic, 1999).

Forensic aspects of the female ejaculate, containing female prostatic fluid, and the female ejaculation phenomenon as such concern two issues : critique of the significance of the acid phosphatase test in evidence of rape in women and the possibility to study modes of secretory mechanisms of the female prostate. Details see in book (Zaviacic, 1999) and in our recent papers (Zaviacic, 2001 ; Zaviacic and Whipple, 2001). In providing expert

evidence of rape in women, the acid phosphatase test was found to be without forensic significance in identifying sperm spots which contain no spermatozoa, since the same acid phosphatase positivity was established in in vitro formed spots of female ejaculate and in in vivo originated spots on used female lingerie. Thus positively reacting spots may originate from the woman herself, without male participation. At present, in the time of forensic DNA analysis, our macroenzyme histochemical findings are of historical rather than forensic importance in providing evidence of rape in women. (Zaviacic, 1999 and references therein).

On the other hand, macroenzyme histochemical findings of acid phosphatase on those parts of worn underwear which are in constant contact with the female genitals are indicative of the existence of continual secretion of the female prostate (Zaviacic, 1999, 2001). Similarly as in the male, initiation of female prostate secretion precedes the onset of puberty (Zaviacic, 1999 and references therein).

The ejaculation mechanism, the biological phenomenon of urethral expulsions in the female, which contrary to the male is not directly involved in reproduction yet remains an attractive phenomenon of female sexuality, is a further mode of evacuation of the prostate in the female. It is most frequently induced by stimulation of the erotically sensitive spot on the anterior wall of the vagina, the so-called G-spot (Zaviacic et al. 1988). Stimulation of the clitoris or suprapubic massage of the urinary bladder neck are relatively rare modes of inducing urethral expulsions (Zaviacic, 1999, 2001, Zaviacic and Whipple, 2001). Asphyxia accompanying strangulation, suffocation and hanging, typical phenomena in the experience of forensic doctors at autopsy, were also found to trigger urethral expulsions (female ejaculation). Knowledge that the female ejaculation phenomenon may potentially play a role also in the motivation of life threatening erotizing paraphilic behavior – sexual asphyxiophilia (Koczwariism) in women could improve diagnosis of these lethal cases often mistaken for suicide rather than fatal

accidents that they actually are (Zaviacic, 1999, 2001 and references therein).

Study of the pathology of the female prostate has remained underresearched due to the long-lasting lack of interest in this female organ shown by urologists, gynecologists, gynecological urologists as well as pathologists. When critically evaluating our present knowledge on the pathology of the female prostate, considerable advancement has been made only in the problem of female prostate carcinoma. Immunohistochemical expression of PSA and PSAP in tumor cells and in metastases has been used to advantage in diagnosing female prostate carcinoma and serum PSA determination has proved beneficial in monitoring the disease (Zaviacic, 1999, and references therein). As far as other diseases of the female prostate are concerned, such as benign prostate hyperplasia, prostatitis (female urethral syndrome), and prostatism, our knowledge is based mainly on case reports while a conceptual description of these diseases is still lacking (Zaviacic, 1999 and references therein). Diseases of the female prostate have been mostly incorrectly diagnosed as diseases of the female urethra and also treated as such. Urologists have not even tried to use the broad possibilities of highly effective and verified conservative treatment and the successful therapeutic strategies applied in the same diseases of the prostate in men (Zaviacic, 1999). Compared to its male counterpart, the female prostate does not only have a similar structure, expression of prostate markers, enzyme equipment, the same exocrine and possibly neuroendocrine function but it may also be the site of origin of similar serious "prostatic" diseases, such as prostatitis, prostatism, benign prostate hyperplasia and carcinoma (Zaviacic, 1999). Expression of the antigen specific for the male prostate, PSA, in female prostate (Skene's paraurethral glands and ducts), along with structural and functional parameters as well as diseases similar to those of the male prostate have provided convincing evidence on the existence of a functional prostate in women. Further use of Skene's

eponym and/or the term paraurethral ducts and glands in referring to the female prostate incorrectly implies that some other structure rather than the prostate is involved and promotes the vestigial notion of this female organ. Simultaneously neglect the terminology decision of FICAT with the term *prostata feminina*.

The fluid of female urethral expulsions (female ejaculate) contains female prostatic components, mainly PSA and PSAP, and also fructose, which clearly confirms, particularly with respect to the first two parameters, participation of the prostate in the production of female ejaculate. The female ejaculate (fluid of female urethral expulsion) exhibits properties important for specific issues in urology, gynecological urology, chronobiology, sexology, forensic sexology, forensic medicine and reproductive medicine. Insight into the female ejaculation phenomenon may lead to resolution of several problems concerning issues of female urinary incontinence, secretory modes of the female prostate, evidence of rape in women, exfoliative hormonal urocytology, as well as the quality of female sexual life, presenting female ejaculation as a normal and often attractive phenomenon of the woman's sexuality (Zaviacic, 1999 and references therein).

Milan Zaviacic* ; Tomas Zaviacic ; RichardJ. Ablin*** ; Jan Breza**** ; Karol Holoman****

*Department of Pathology.

**Second Department of Obstetrics and Gynecology, Comenius University School of Medicine and Faculty Hospital, Bratislava, Slovak Republic.

***Innapharma, Park Ridge, New-Jersey, USA.

****Department of Urology, Derer's University Hospital, Bratislava, Slovak Republic.

Pr Milan Zaviacic,
Professor and Head,
Department of Pathology,
Comenius University School
of Medicine,
Sasinkova 4
811 08 Bratislava
Slovak Republic (Slovakia)
E-mail : zaviacic@fmed.uniba.sk